Dermatopathology Slide Review Part 29

Paul K. Shitabata, M.D.
Dermatopathology Institute

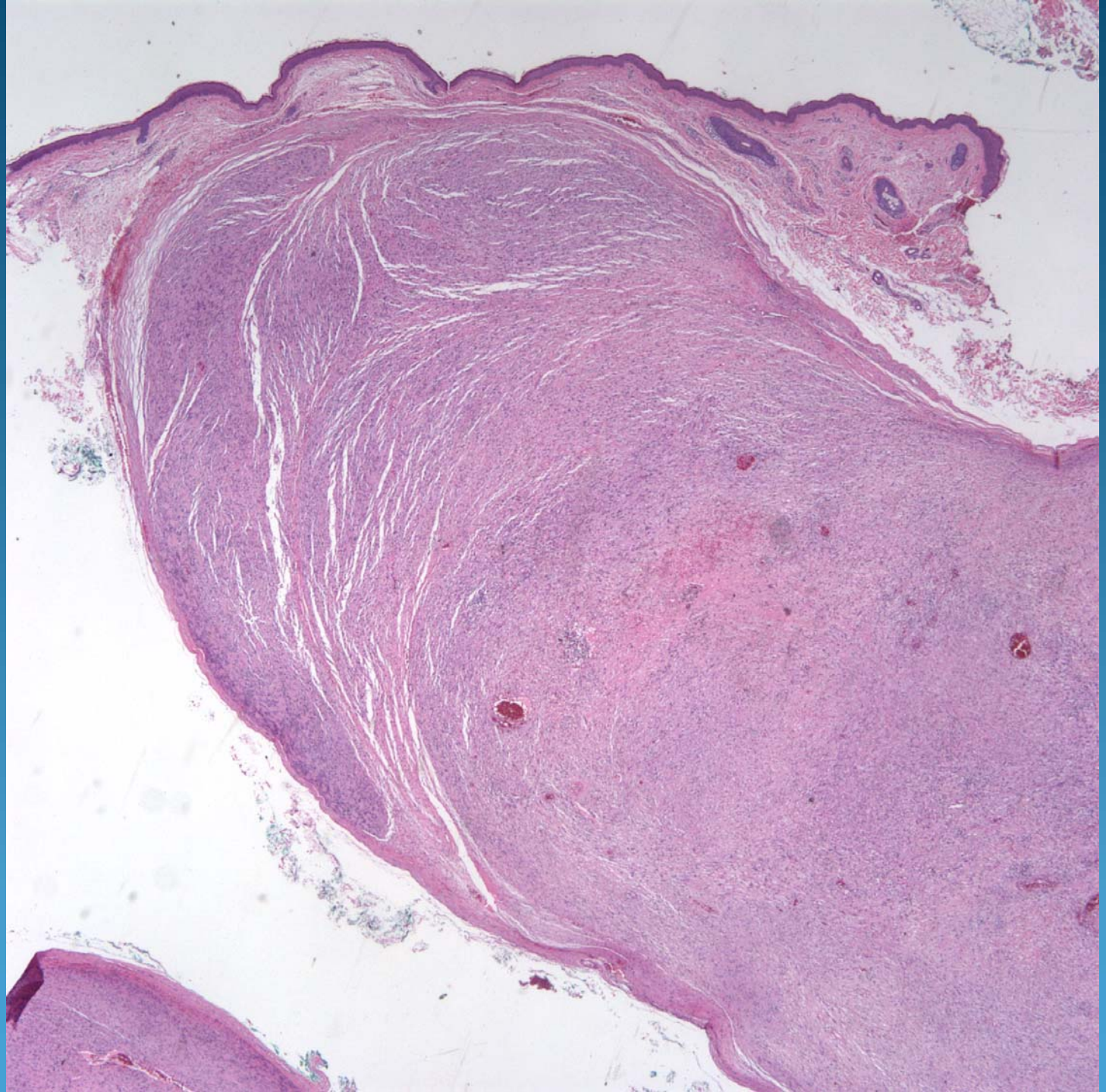

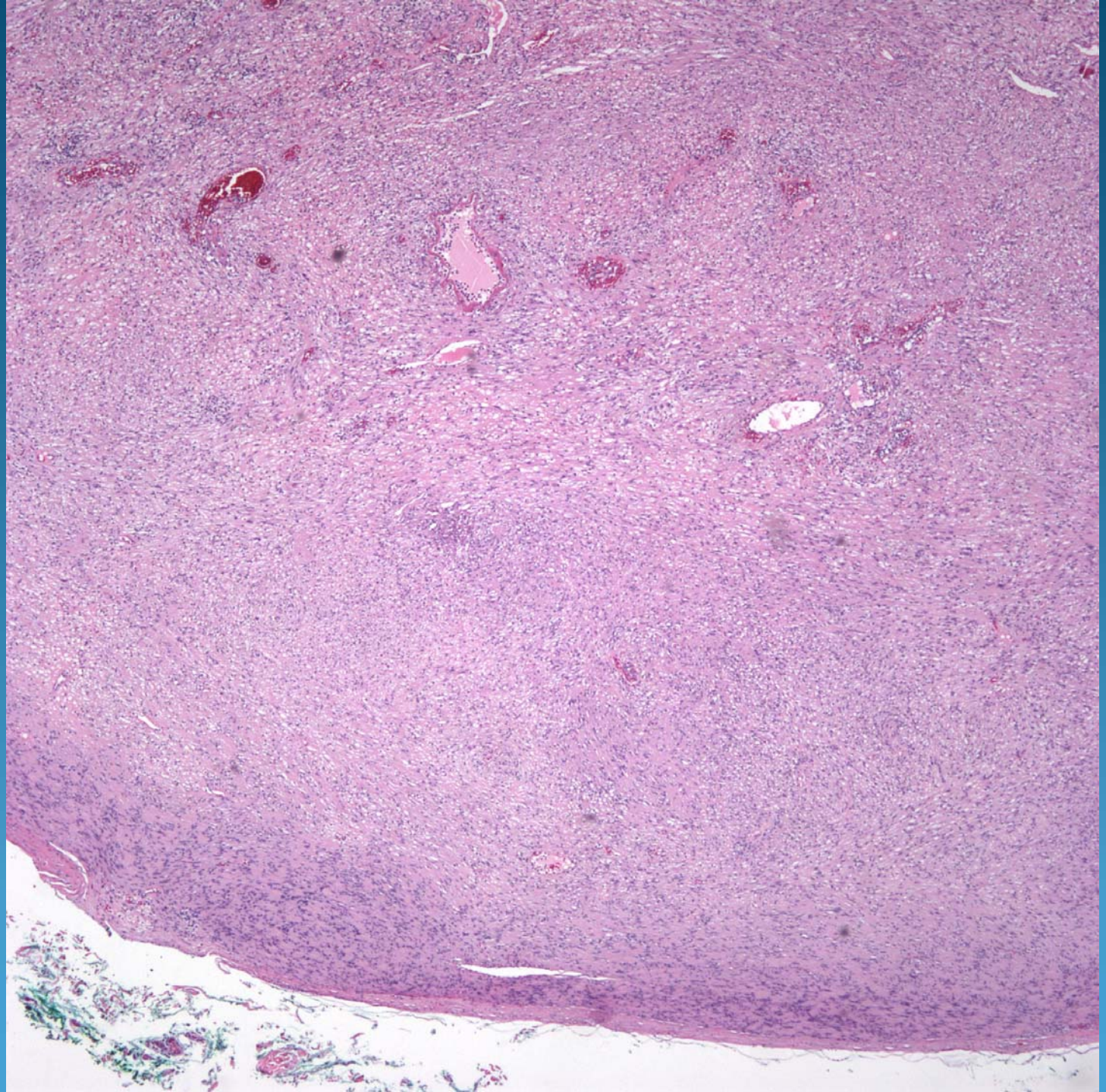

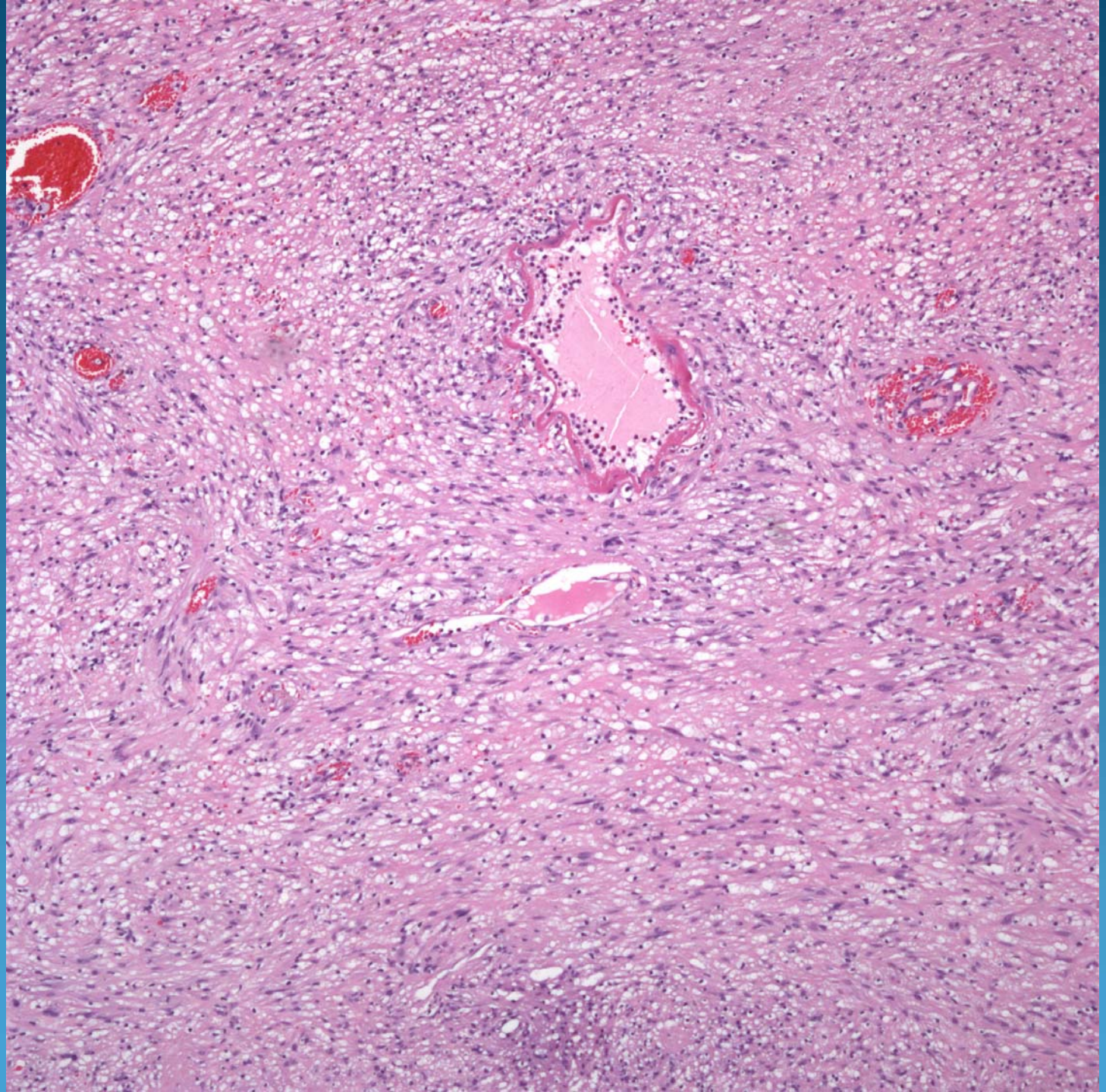

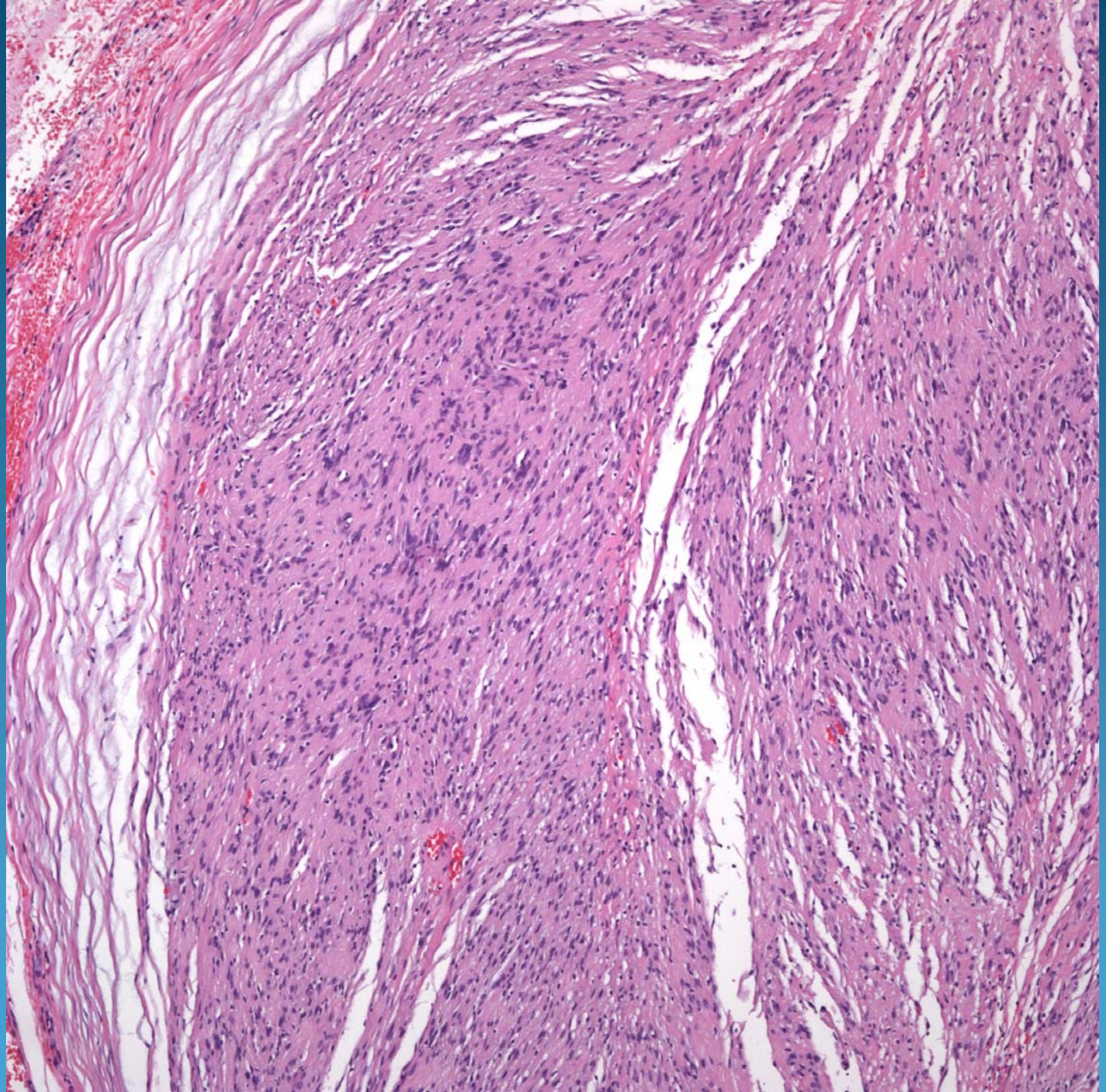

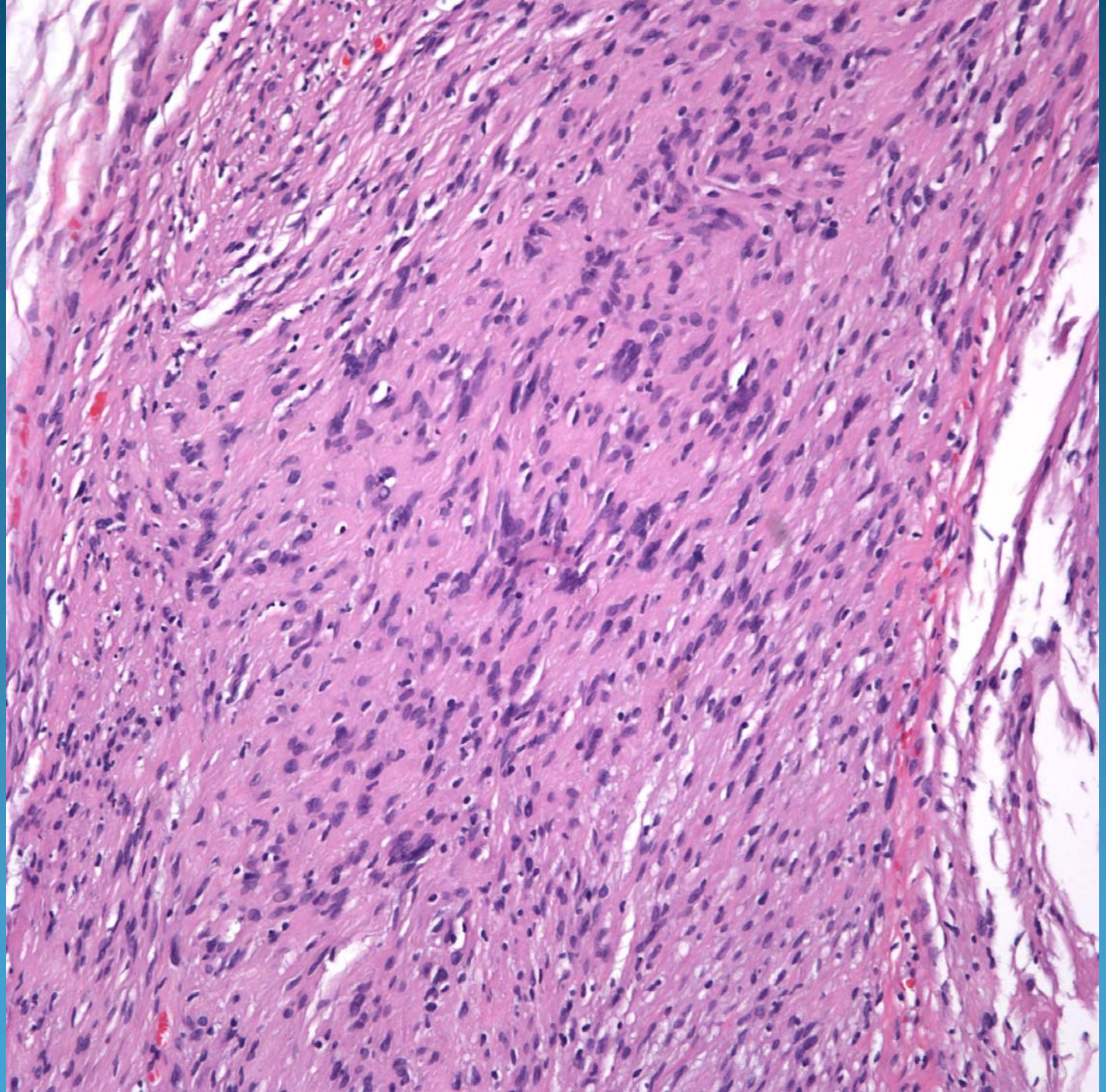

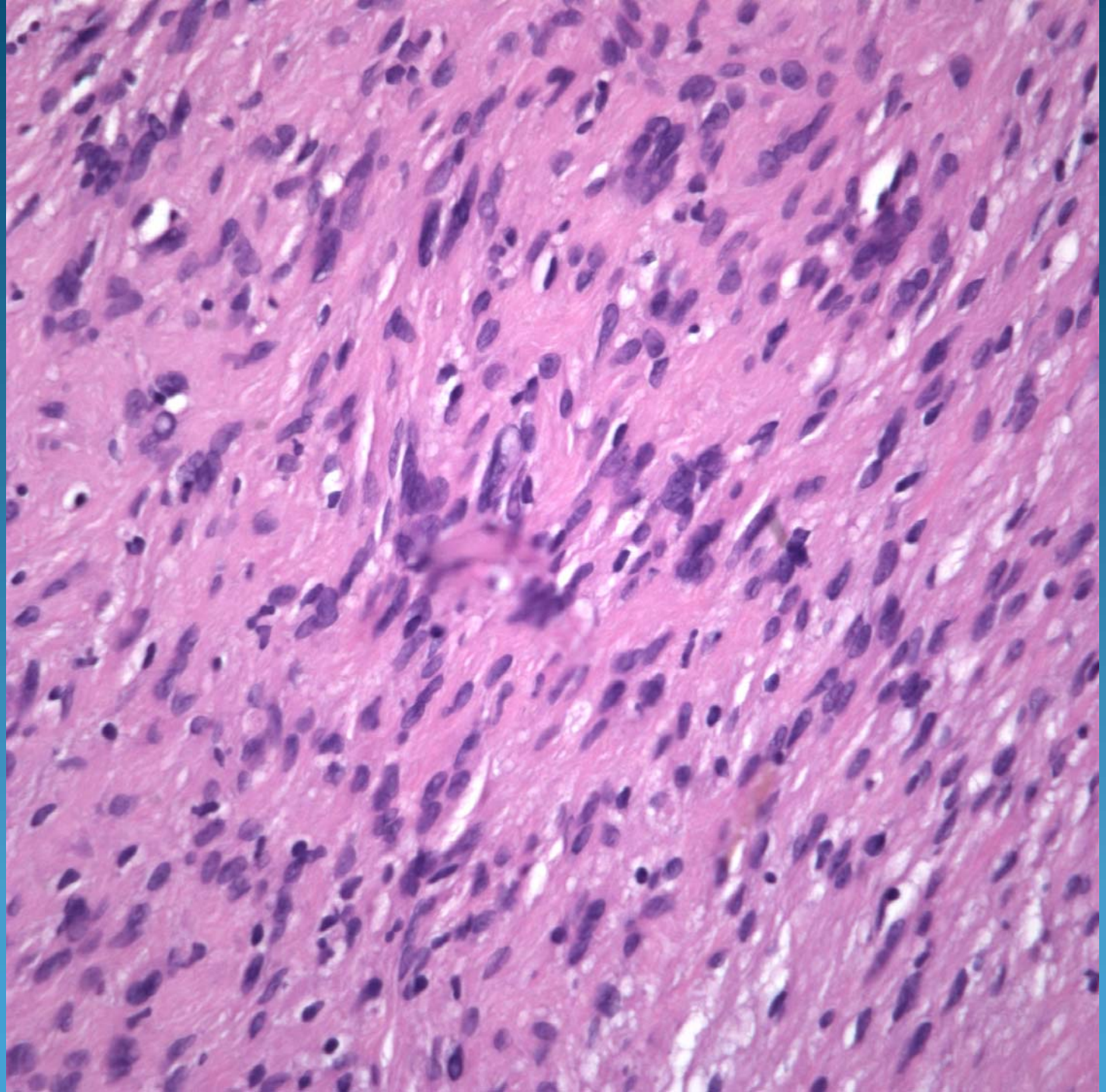

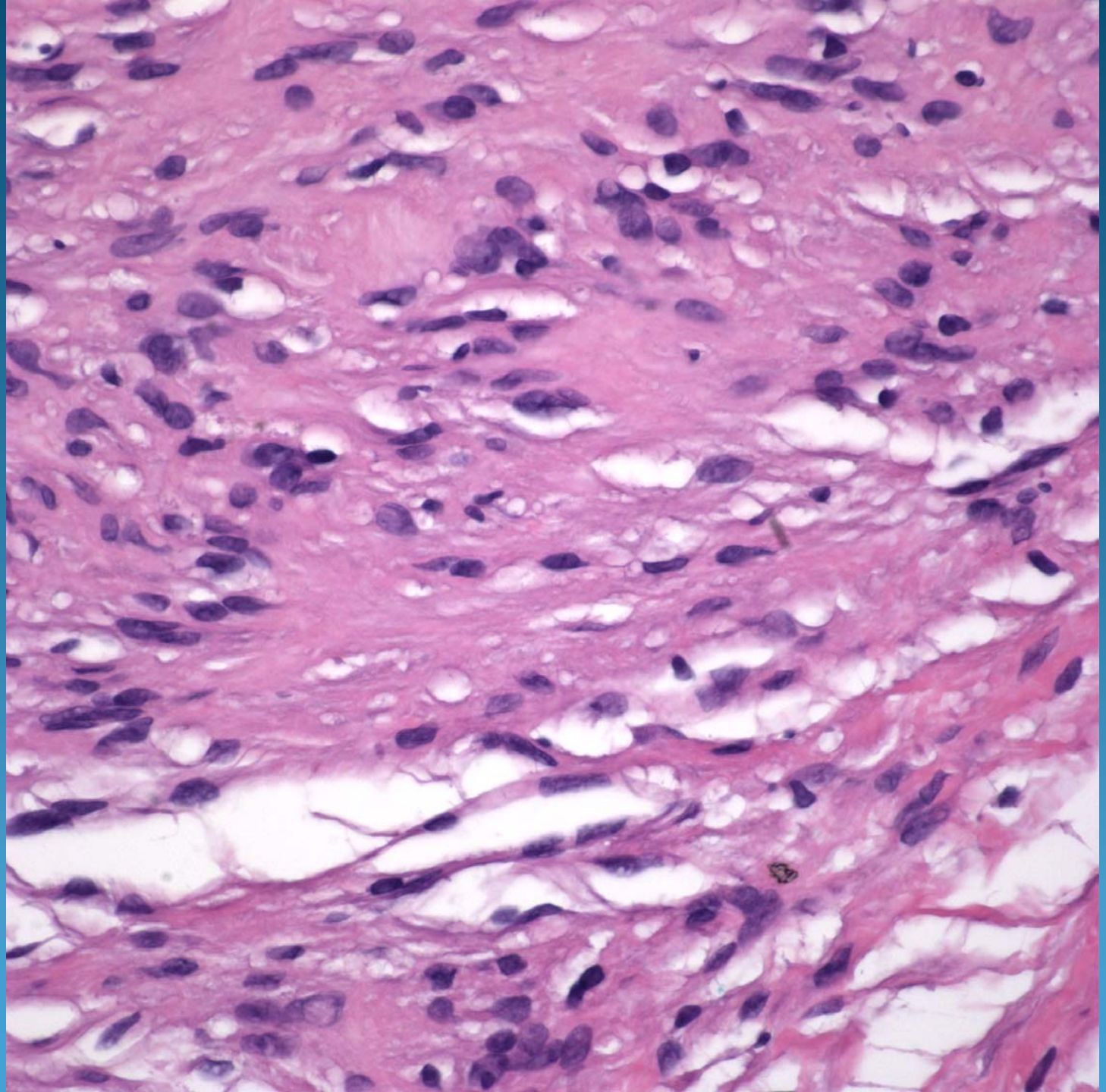

Cutaneous Schwannoma

Pearls

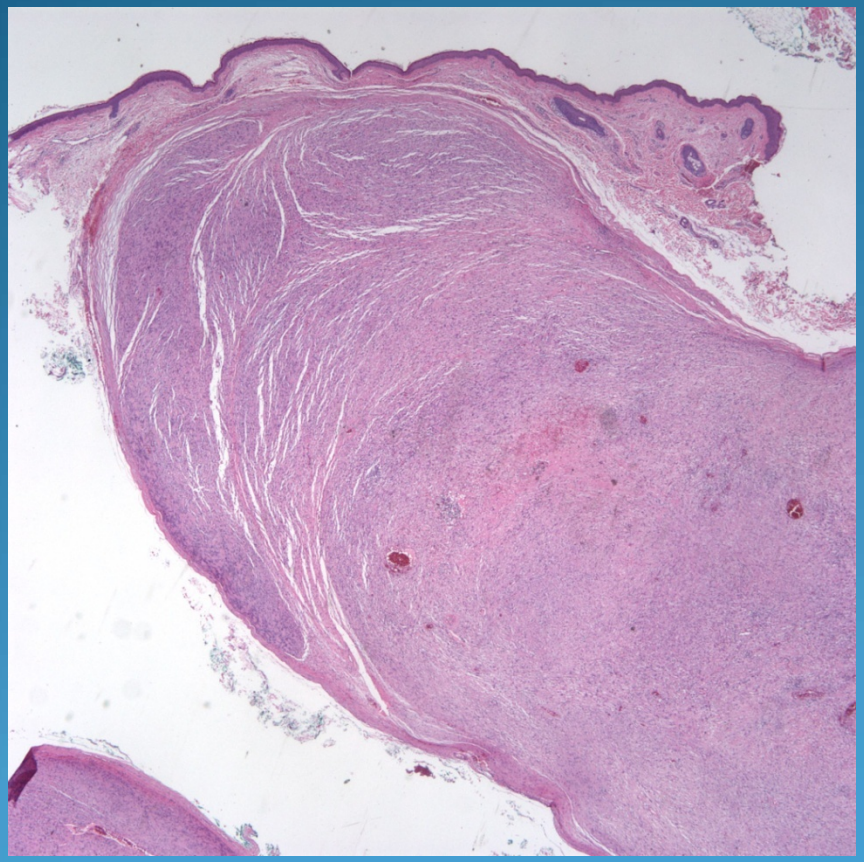

- Superficial variant of deep soft tissue schwannoma
- Similar histopathology with good circumscription
- Antoni A and Antoni B type fibers with Verrocay bodies
- Hyalinization around vessels
- DDX: Neurofibroma

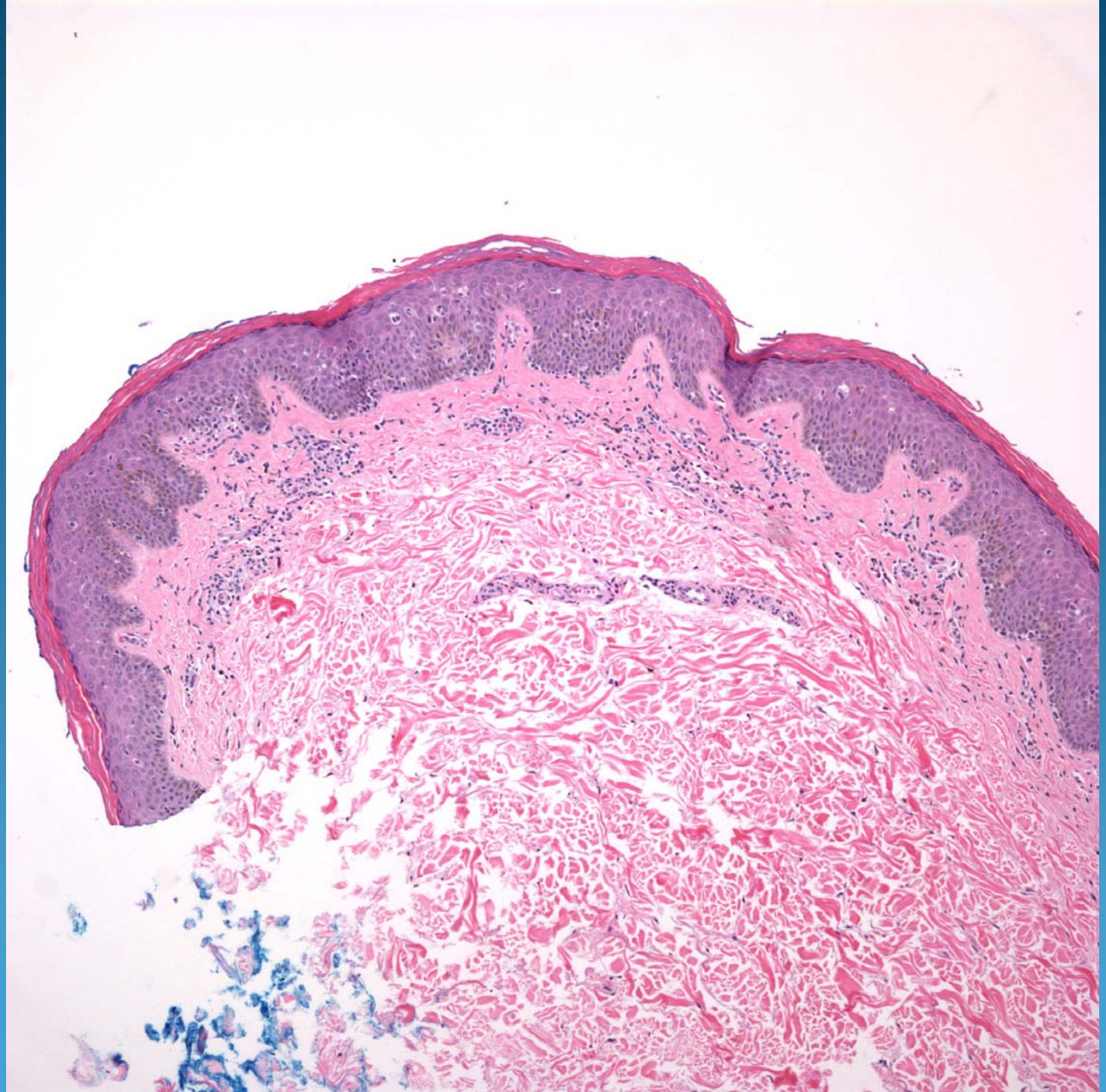

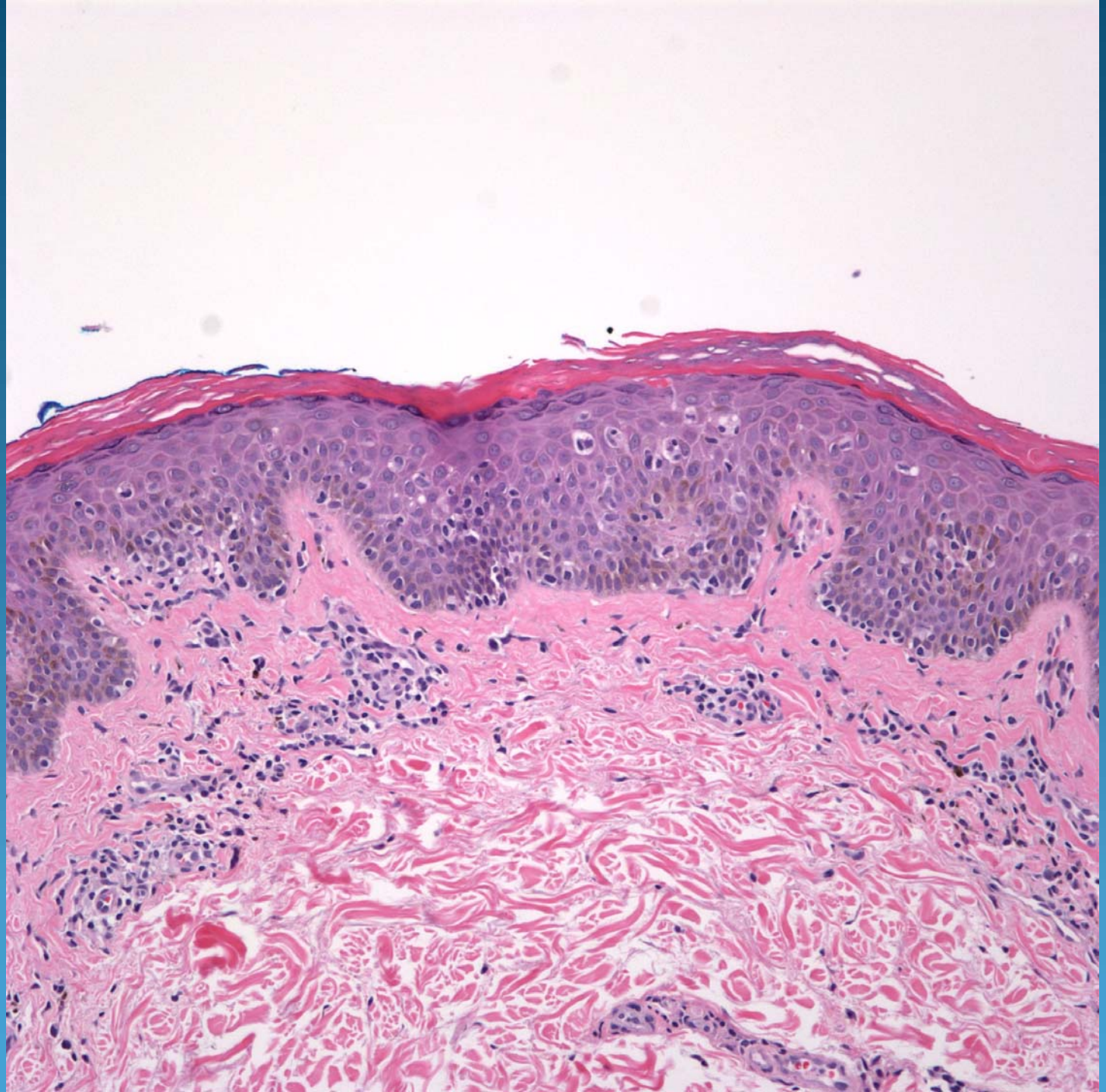

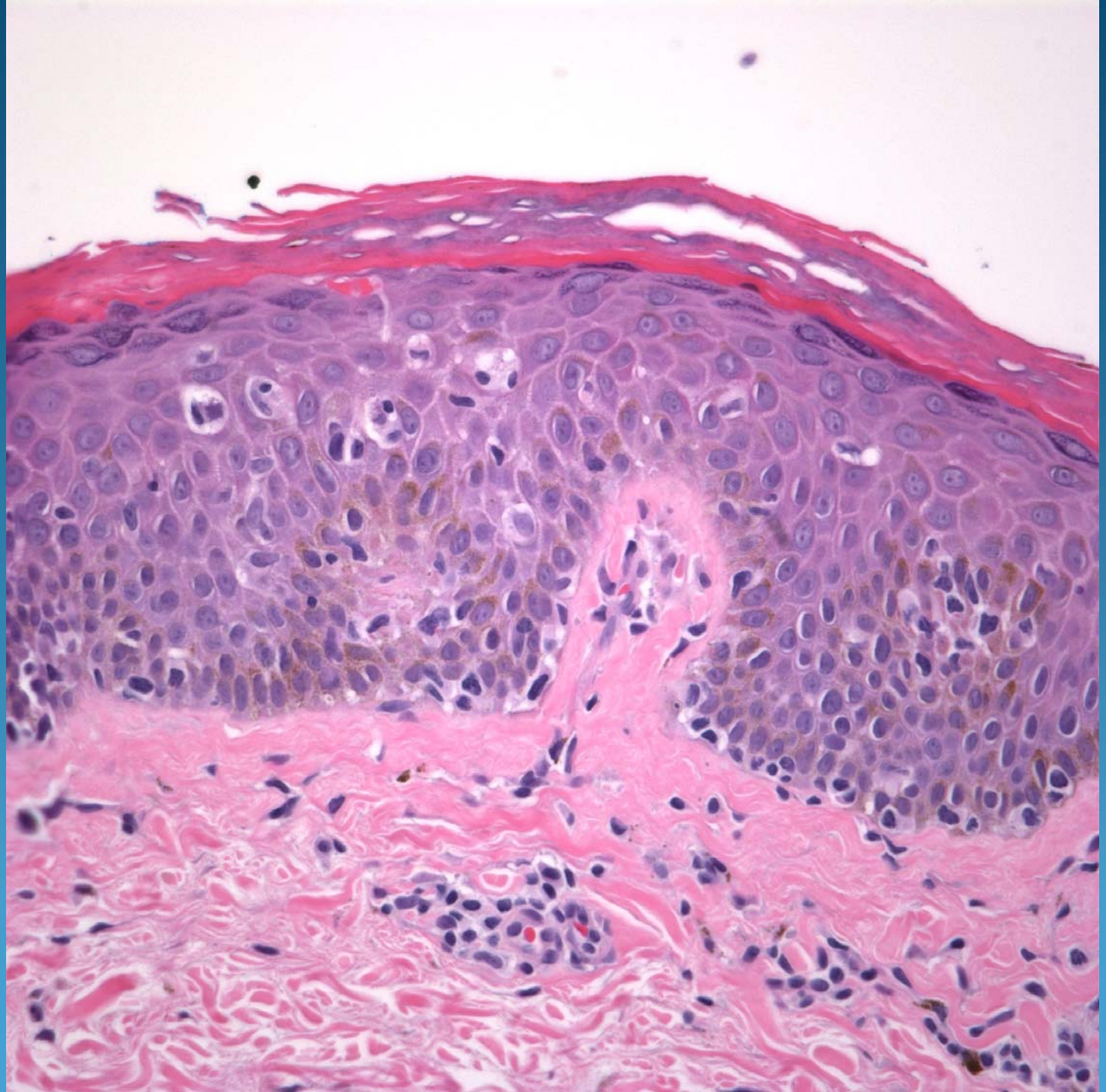

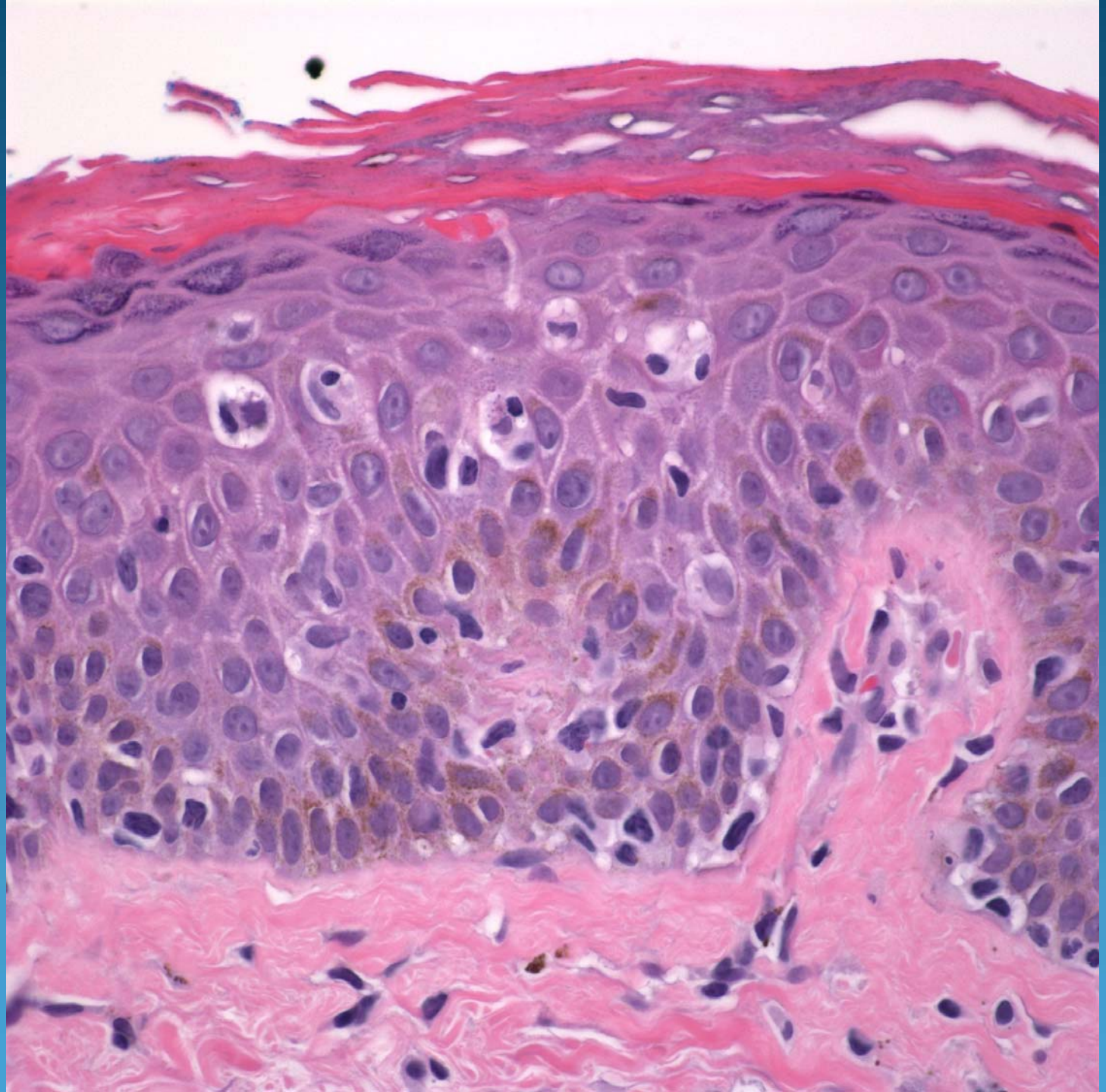

Mycosis Fungoides-Patch Stage

Pearls

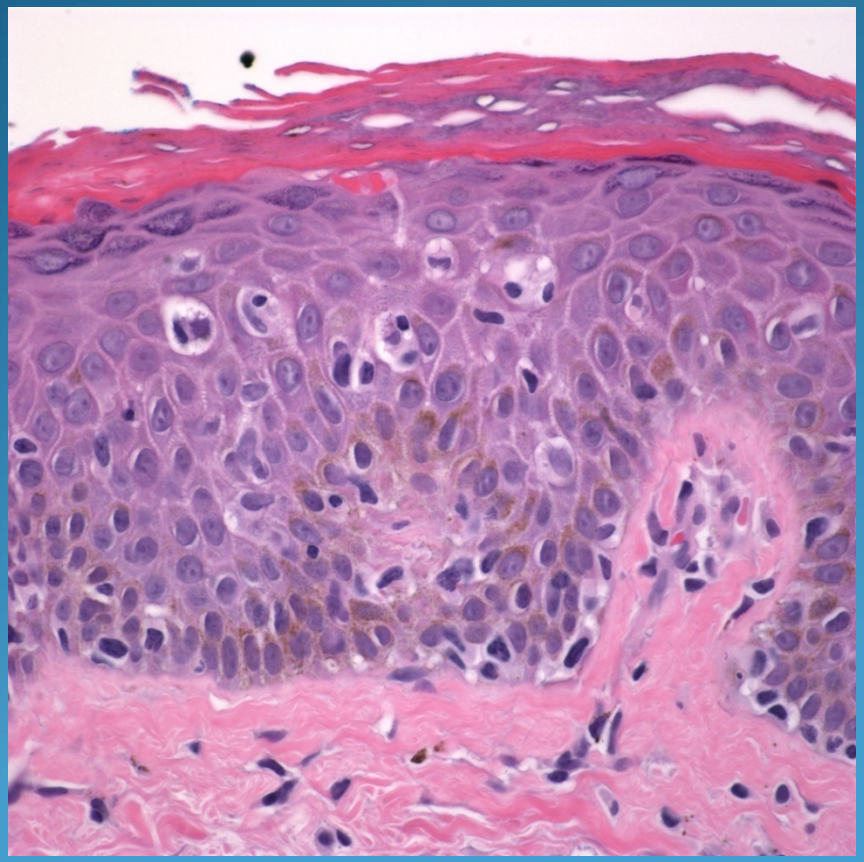

- Atypical lymphocytes intercalating with basal keratinocytes
- Pautrier microabscesses
- Hyperchromatic and hyperconvoluted lymphocytic nuclei

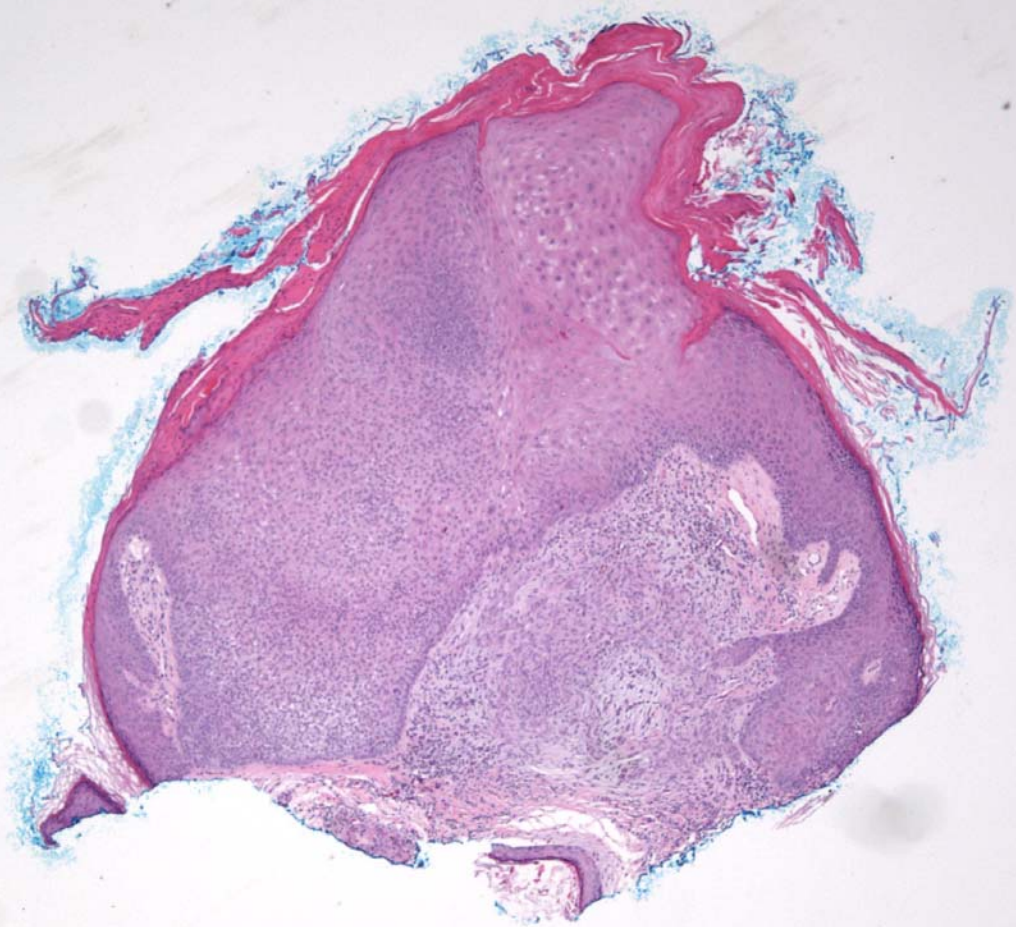

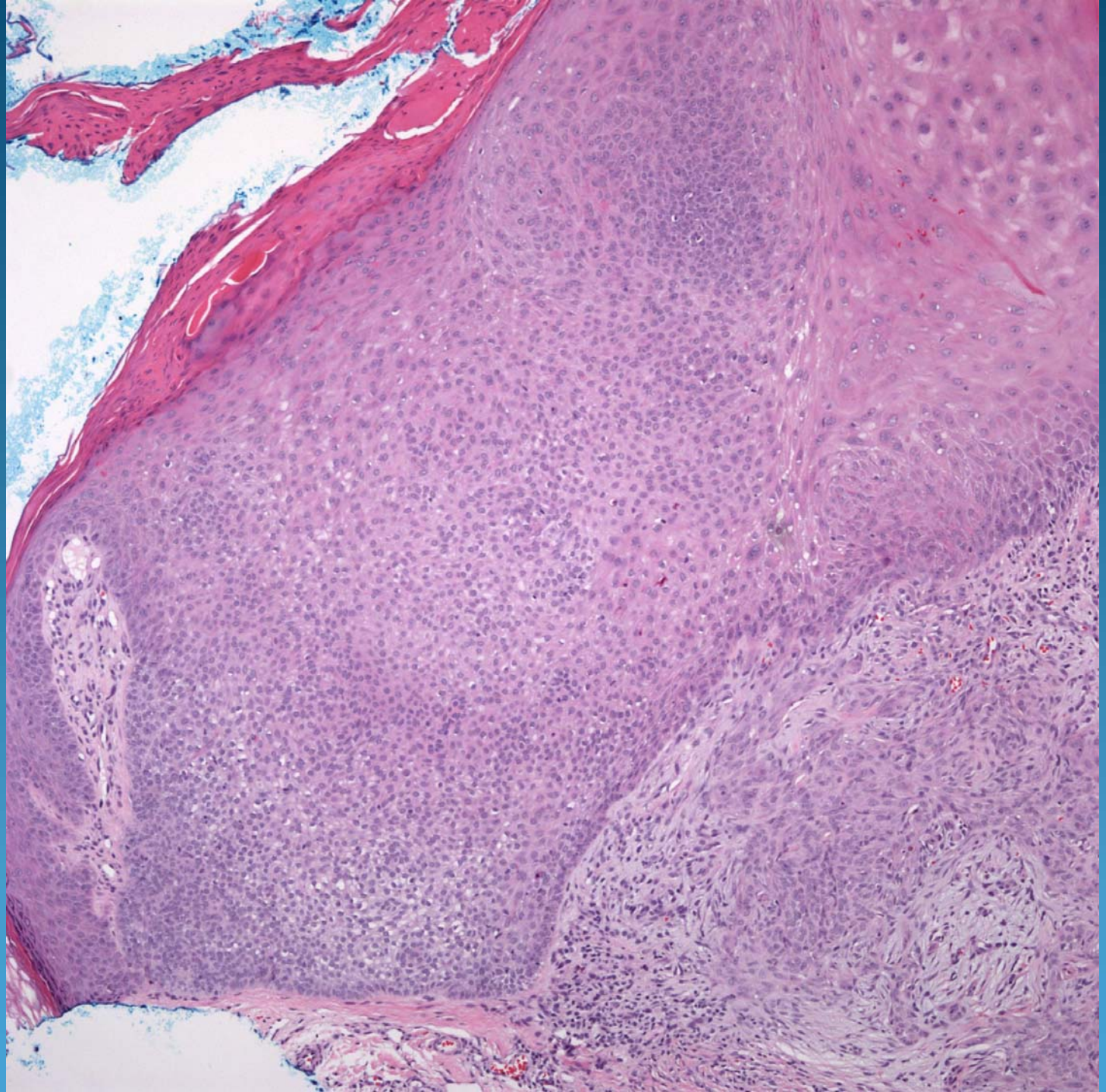

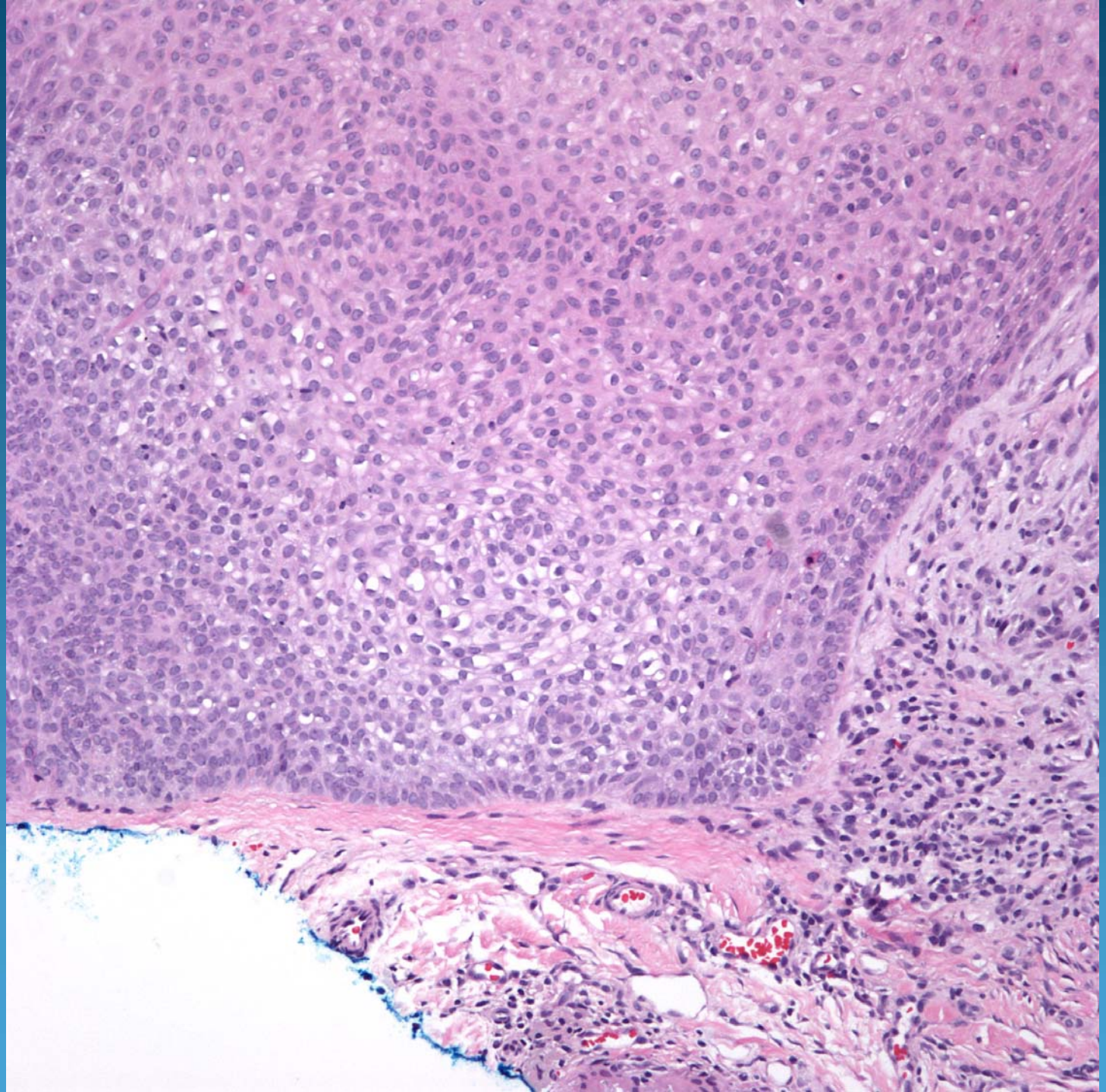

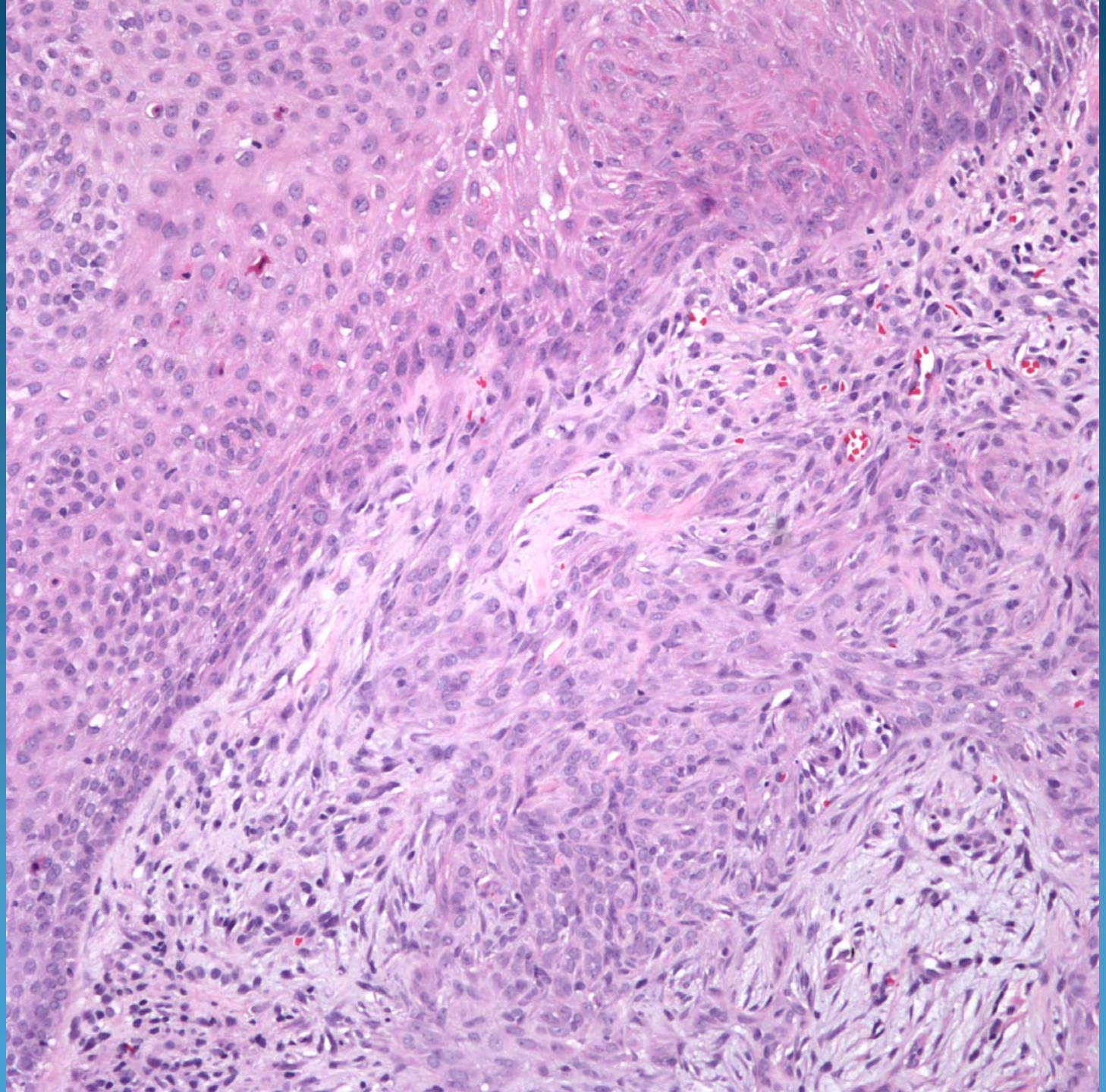

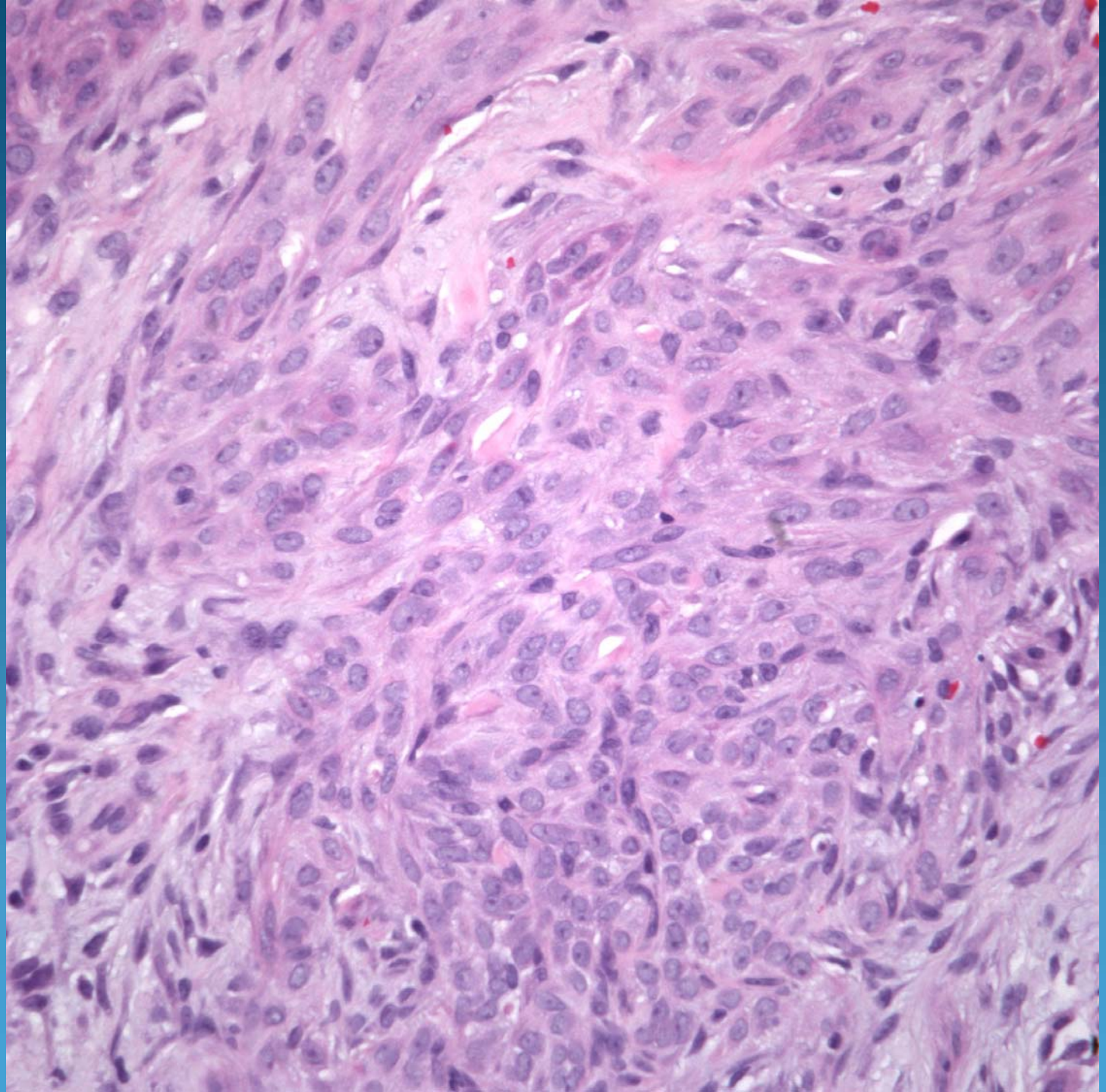

Desmoplastic Trichilemmoma

Pearls

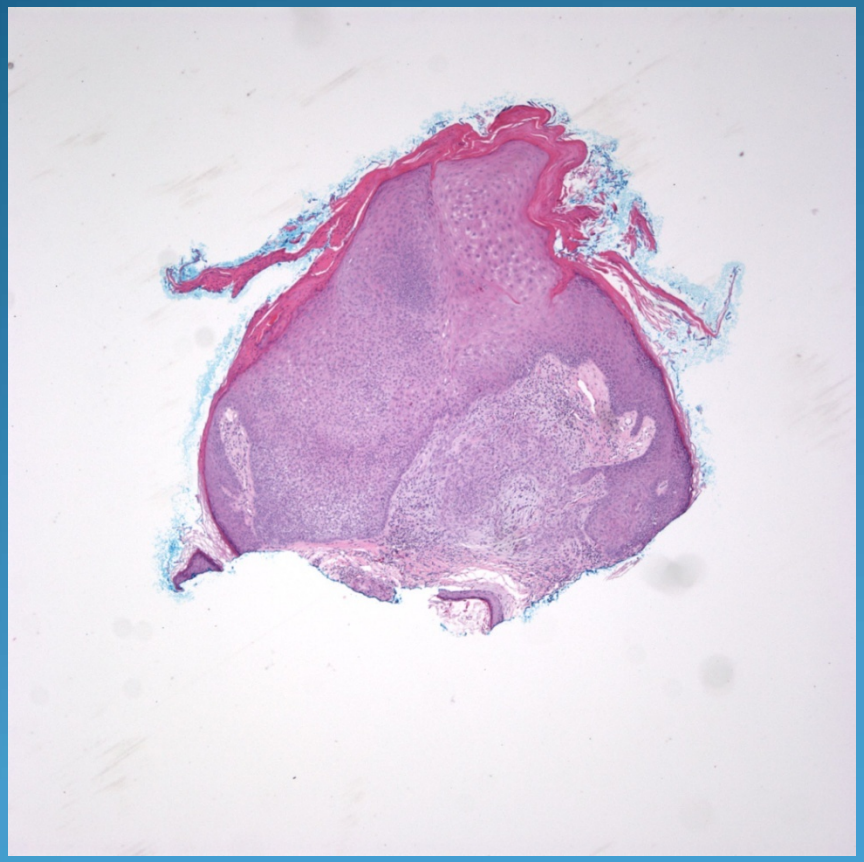

- Verruciform architecture
- Downward invagination of epidermis with characteristic clear cell palisading of basal layer
- Accentuated basement membrane
- Abrupt transition of basaloid cells to infiltrating epithelial cells

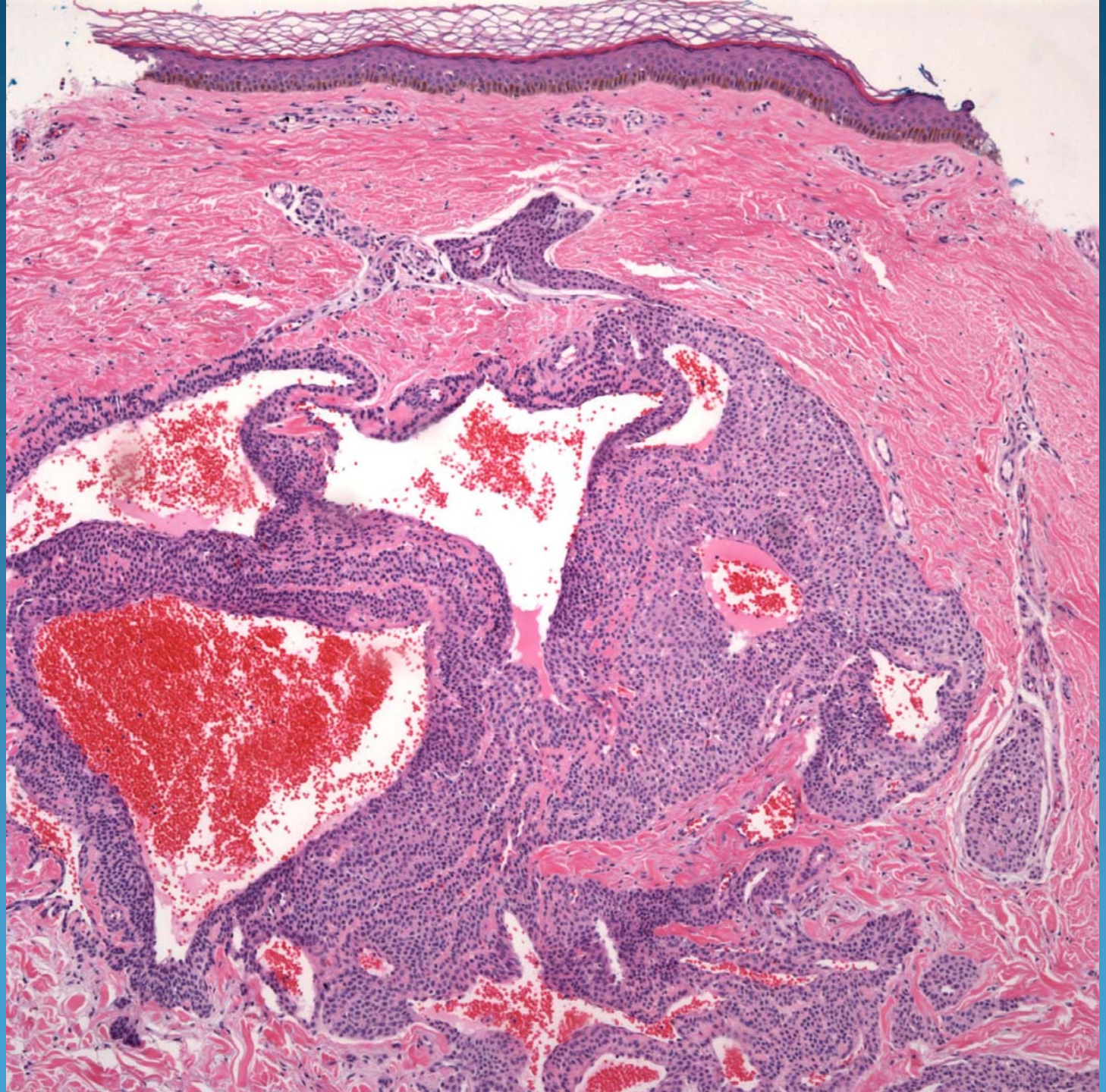

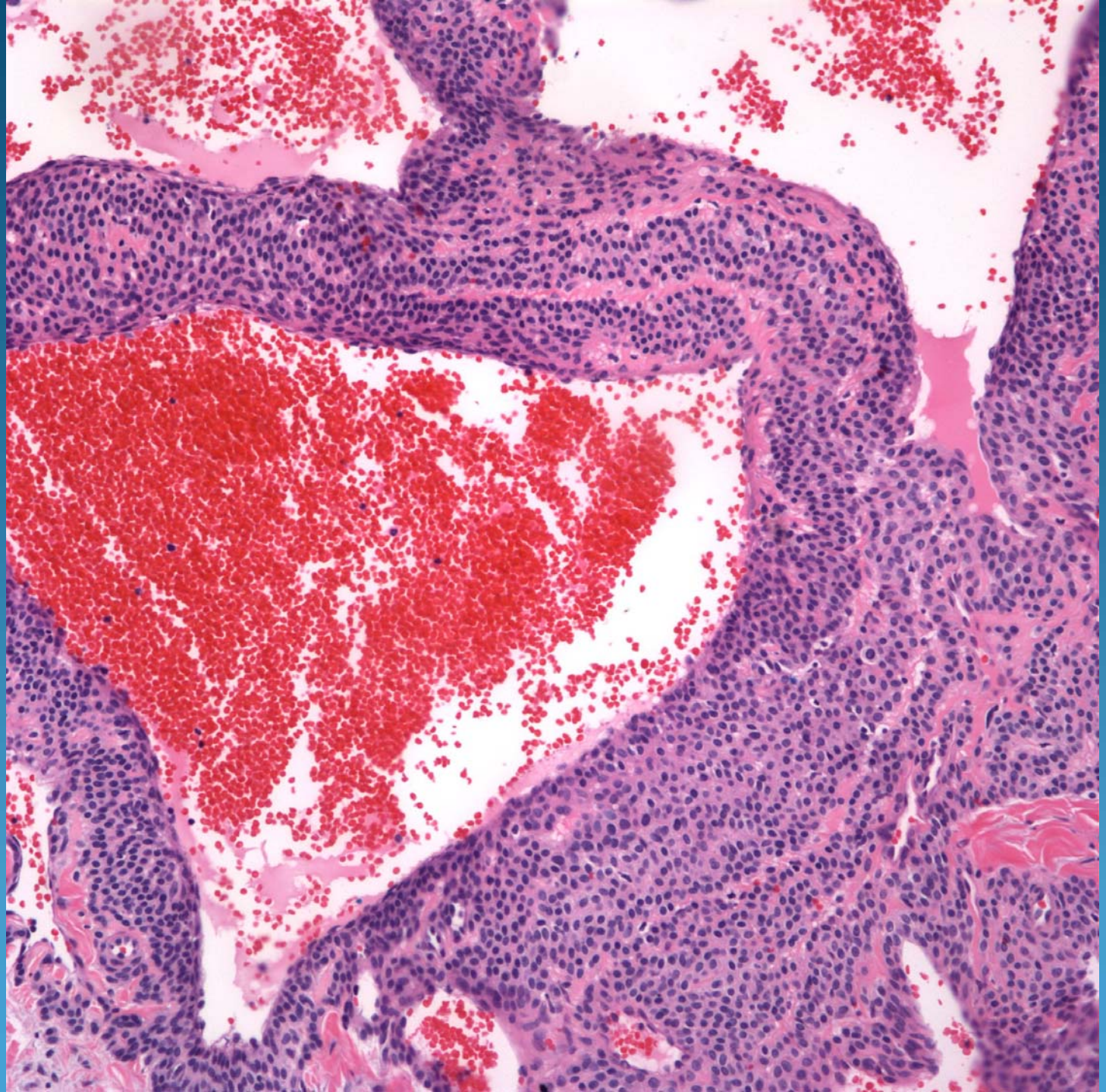

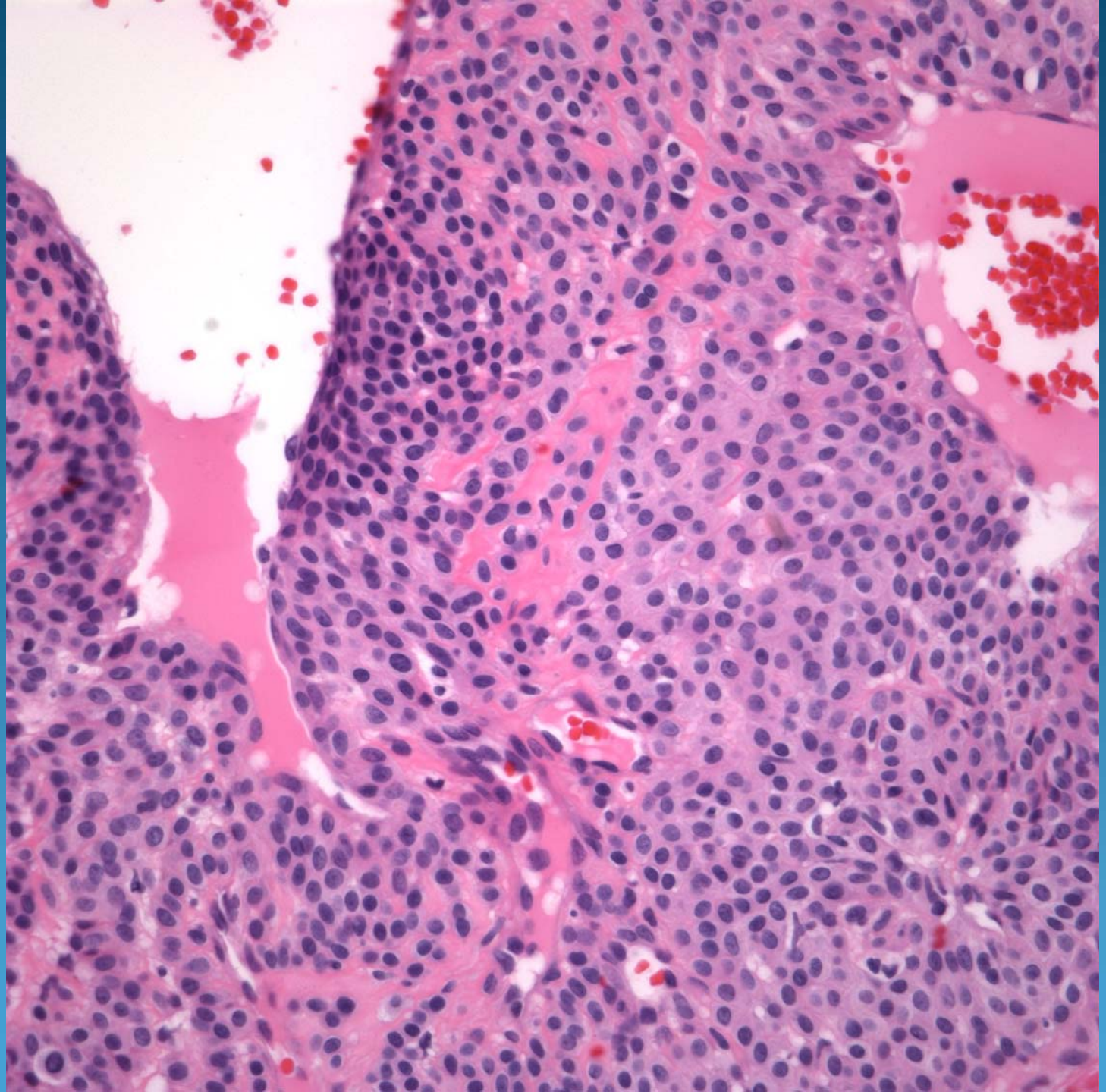

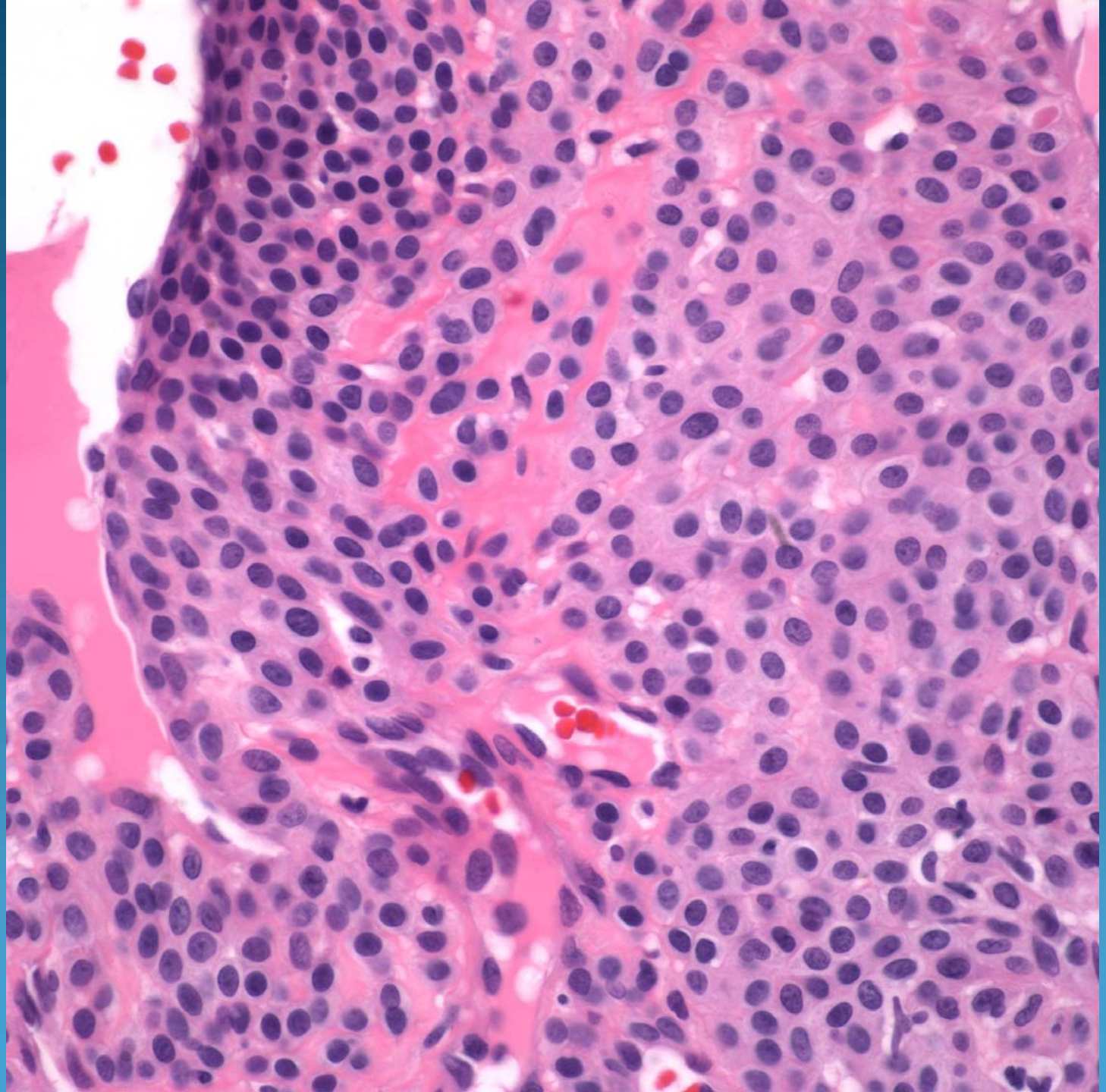

Glomus Tumor

Pearls

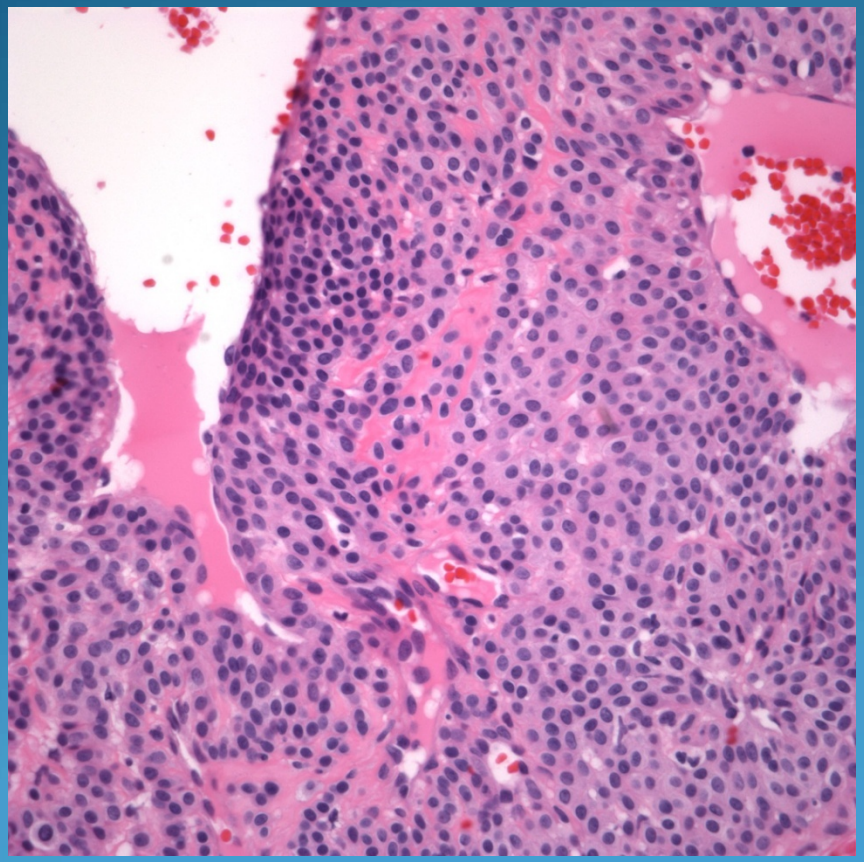

- Polygonal cells (fried-egg cells) with distinct cytoplasmic borders
- Usually intimately associated with thick walled vessels
- Minimal atypia

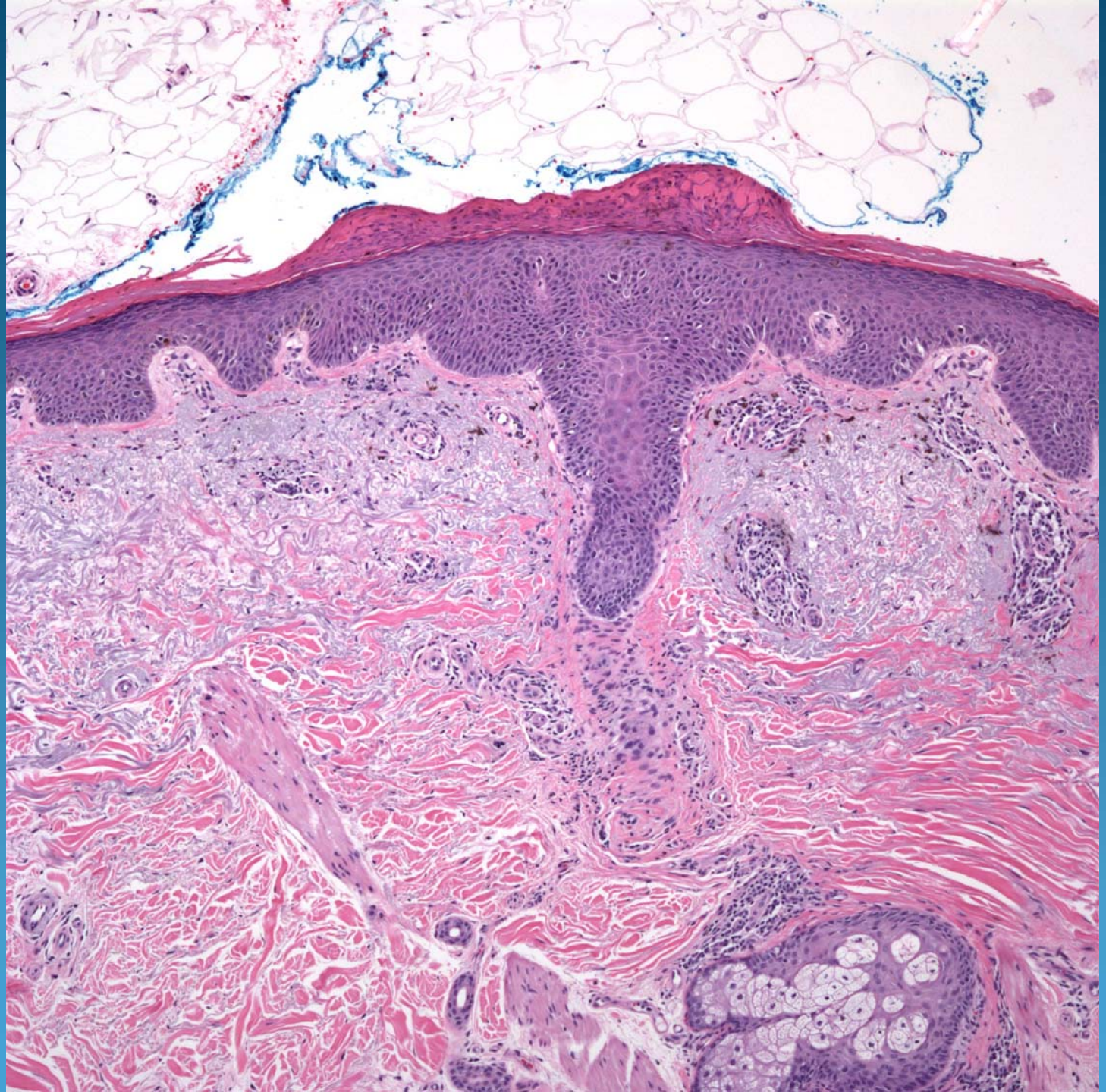

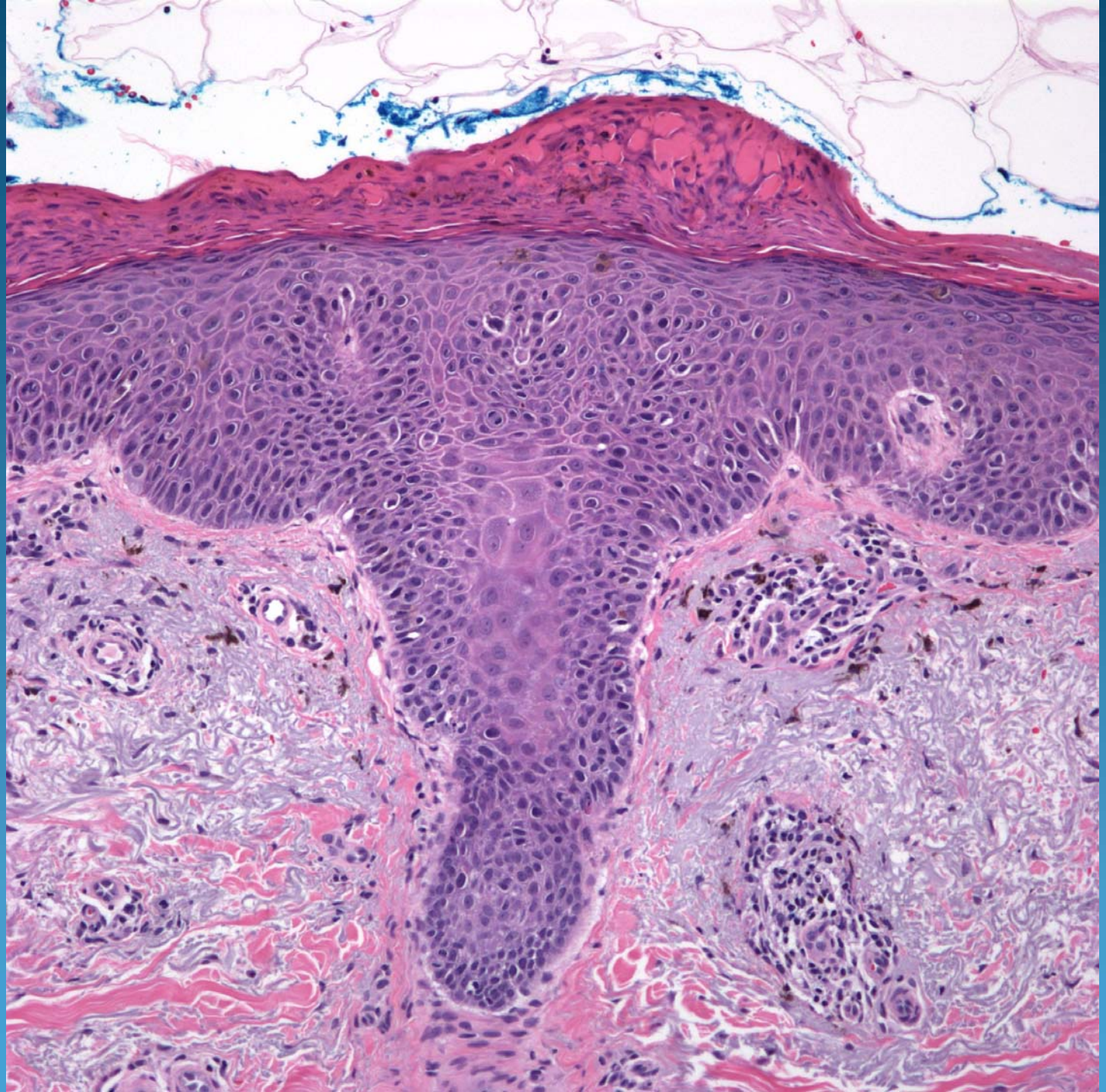

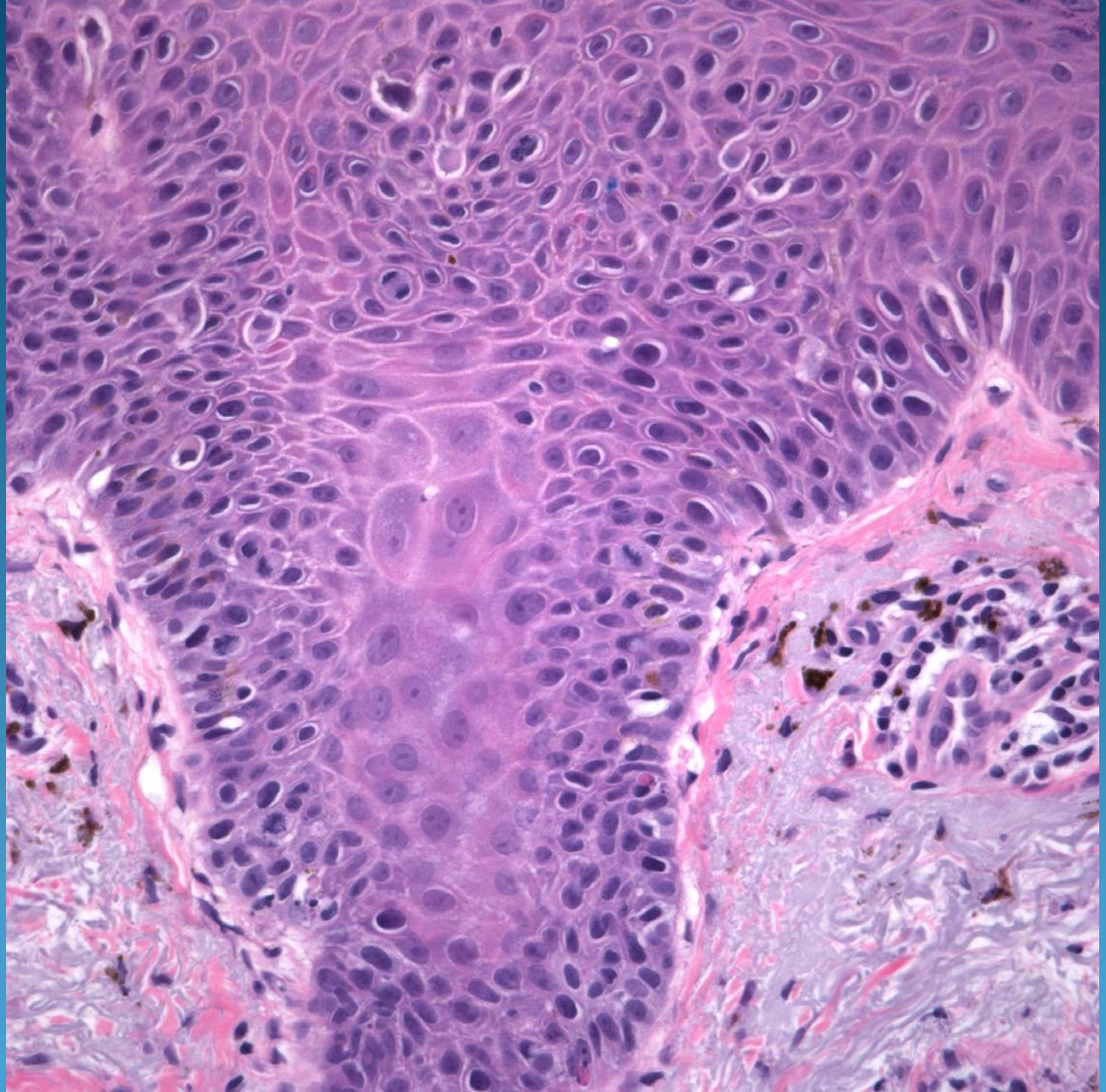

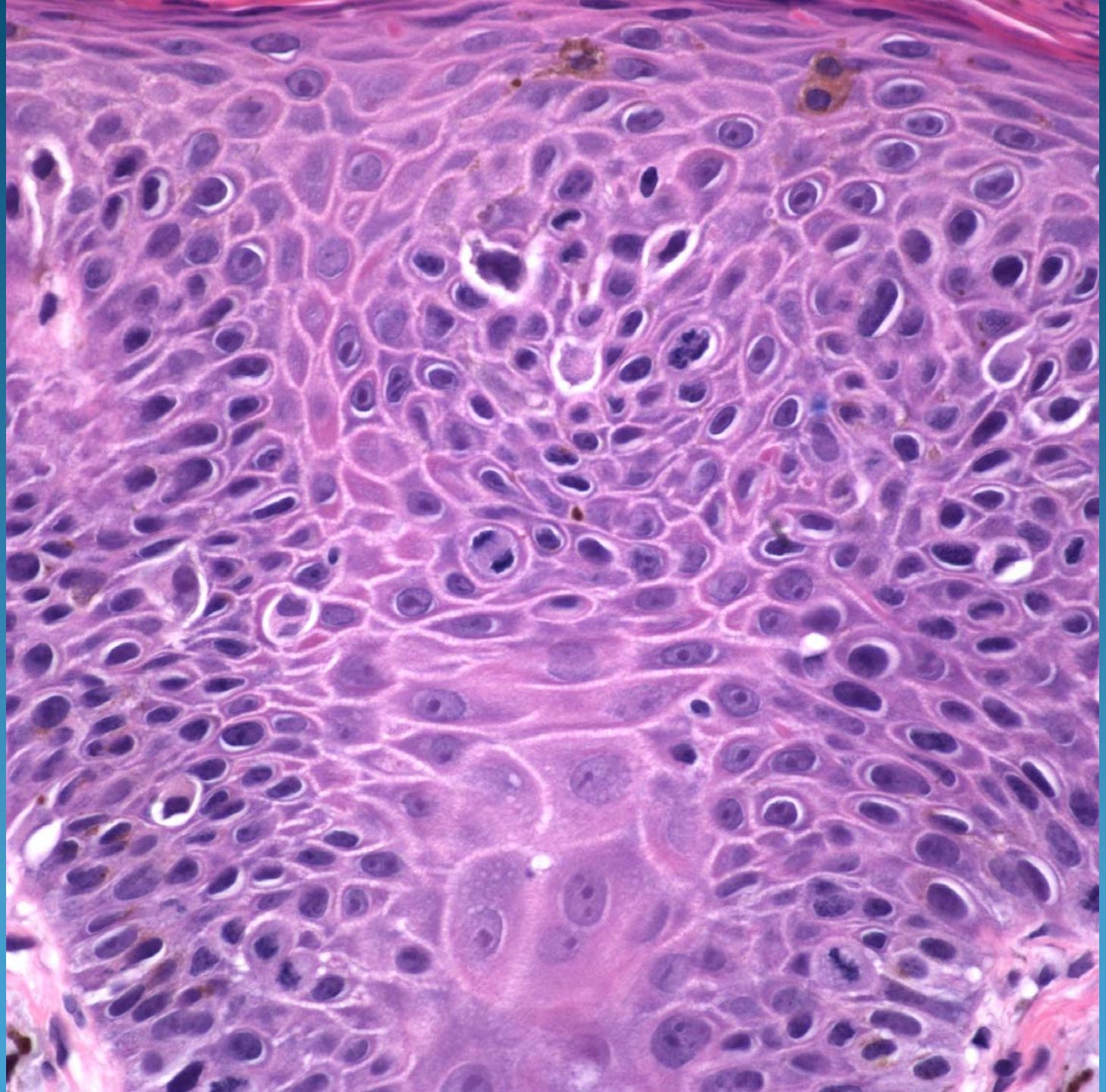

Malignant Melanoma in Situ-Superficial Spreading, Preodominately Amelanotic Type

Pearls

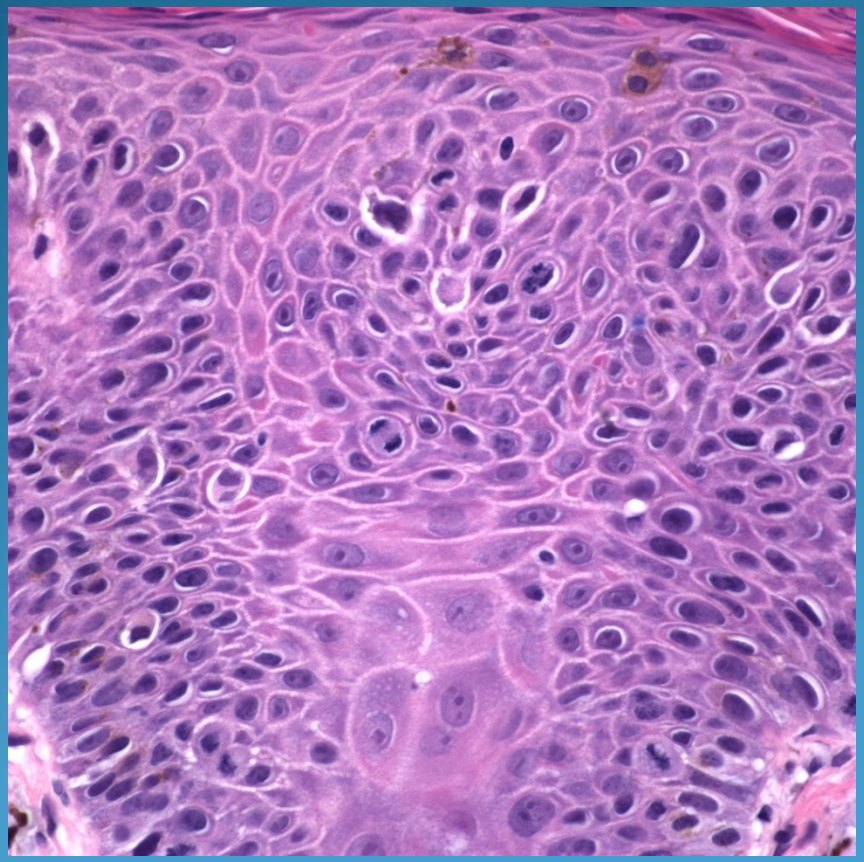

- Intraepithelial "buckshot" pattern of cytologically malignant melanocytes
- Lacking melanin pigment
- May need IHC to confirm melanocytic origin
- DDX: Bowen's disease, Paget's disease